



PATIENT PRESENTING CLINICAL SIGNS

- Lola Humphries
- Patient significantly proteinuric (UPC 7) (Creatinine 1.9)
 - Concern for tubular structures near kidneys without blood flow on AUS
 - Abnormal PE/Chem/CBC/UA Results: (UPC 7) (Creatinine 1.9)

SPECIES

Canine

COMPUTED TOMOGRAPHIC STUDY OF THE ABDOMEN

Plain and post contrast studies are available for review.

BREED

German Shepherd
Mix

COMPUTED TOMOGRAPHIC FINDINGS

Both renal veins drain into a dilated right azygous vein rather than in the normal caudal vena cava pathway. The caudal abdominal vena cava ends at the level of the kidneys (abdominal caudal vena cava aplasia). The renal veins are dilated likely due to abrupt change of caliber and forward flow obstruction when entering the significantly smaller right azygous vein.

SEX

FS

The right azygous vein is relatively dilated, but otherwise normal in course and patency.

AGE

4yr

The portal vein anatomy is normal. The hepatic veins drain into the usual thoracic segment of the caudal vena cava. There is no evidence of a portosystemic shunt (PSS and caudal vena cava aplasia can co-occur, which is not the case in this patient).

Small gallbladder microliths are seen without evidence of obstruction.

INTERPRETED BY

Nele Eley (Ondreka),
DVM Dr. med. vet.,
DipECVDI

No other abdominal masses or structural abnormalities are detected.

COMPUTED TOMOGRAPHIC DIAGNOSIS

- Congenital aplasia of the caudal vena cava with azygous continuation, resulting in alternative pathway drainage of the renal veins into the right azygous vein.
- Mild gallbladder microlithiasis without obstruction.

HOSPITAL NAME

CARE Surgical
Center

INTERPRETATION OF FINDINGS & FURTHER RECOMMENDATIONS

The CT study reveals a congenital vascular anomaly. The observed pattern represents a rare vascular anomaly in which the caudal abdominal vena cava fails to continue normally, and systemic venous return from the kidneys is rerouted via the azygous vein. This is usually incidental, but can contribute to slow, sluggish renal venous return as evidenced here by the dilation of the renal veins.

Proteinuria and mild azotemia may be influenced by the altered renal hemodynamics, although coexisting primary renal disease cannot be excluded.

REFERRING VET

Dr Samantha
Parkinson

INVOICE

23865

The increased venous pressure could predispose to renal congestion or thrombosis, although this is uncommon. The vascular anomaly is also important to note during any abdominal surgery or interventional procedures, or central venous catheterization, as the standard venous anatomy is altered in this patient.

DATE

02/11/2026

Consider a nephrology follow-up.



PATIENT

Lola Humphries

SPECIES

Canine

BREED

German Shepherd
Mix

SEX

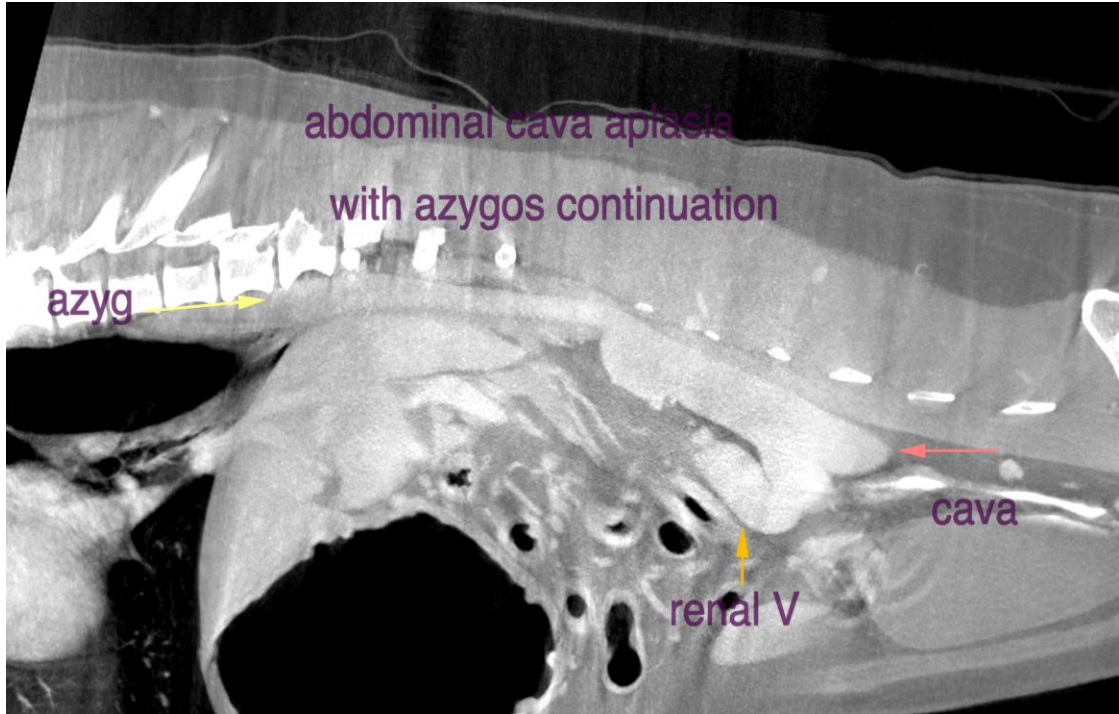
FS

AGE

4yr

INTERPRETED BY

Nele Eley (Ondreka),
DVM Dr. med. vet.,
DipECVDI



The information and recommendations provided are based on the images presented by the referring veterinarian. No evaluation can be communicated regarding pathology that was not visible in the image/video clips provided.

Thank you for this referral. If the clinical or image interpretation does not parallel your findings or if I can be of any further assistance please contact me.

HOSPITAL NAME

CARE Surgical
Center

Nele Eley (Ondreka), DVM, Dr. med. vet., DipECVDI
European Specialist in Veterinary Diagnostic Imaging, Cert. Radiology,
Senior lecturer University of Giessen/Germany, Veterinary Faculty, Department of Radiology.
info@sonopath.com

REFERRING VET

Dr Samantha
Parkinson

INVOICE

23865

DATE

02/11/2026



PATIENT

Lola Humphries

SPECIES

Canine

BREED

German Shepherd
Mix

SEX

FS

AGE

4yr

INTERPRETED BY

Nele Eley (Ondreka),
DVM Dr. med. vet.,
DipECVDI

HOSPITAL NAME

CARE Surgical
Center

REFERRING VET

Dr Samantha
Parkinson

INVOICE

23865

DATE

02/11/2026